

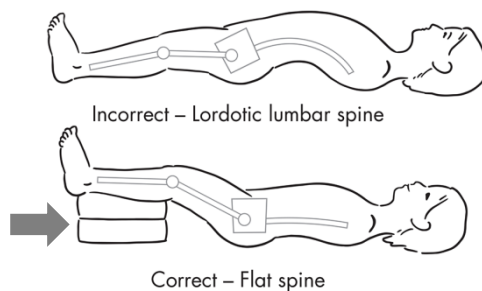
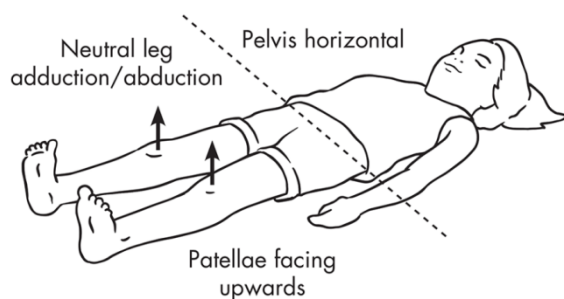
Radiology Protocol for Cerebral Palsy Hip Surveillance

Study Requested: Supine Anterior-Posterior Pelvis X-Ray

Positioning details:

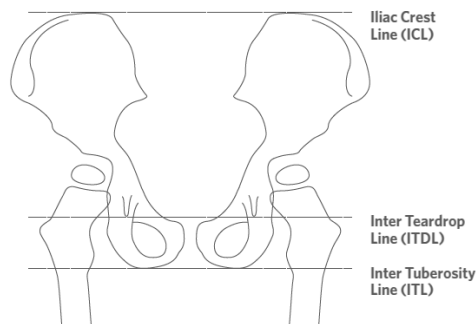
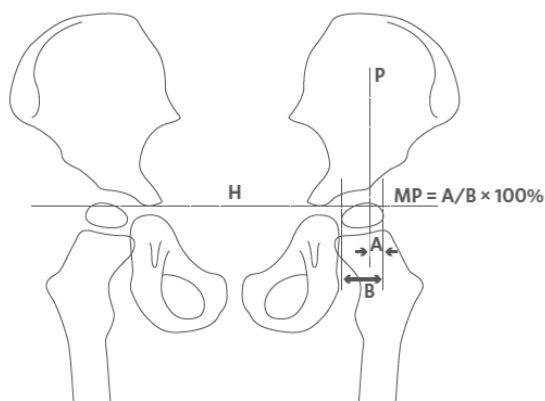
Children should be positioned as follows:

- Pelvis horizontal
- Hips and legs in neutral adduction/abduction
- Patella pointing forward (feet may not necessarily point up)
- If a hip flexion contracture is present, position the lower legs on pillows to prevent anterior pelvic tilt and lumbar lordosis



Reason For Request:

Please report the Migration Percentage (MP) for **each hip**, defined as the amount of ossified femoral head that is not covered by the ossified acetabular roof. In the left-sided figure below, **Migration Percentage = A / B x 100%**



“H” line – Hilgenreiner’s horizontal line connecting open tri-radiate cartilage

- If tri-radiate cartilage is closed, horizontal may be established by the alternative lines shown in the right-sided image, the Iliac Crest Line, Inter Teardrop Line, or Inter Tuberosity Line

“P” line – Perkin’s perpendicular line at lateral edge of ossified acetabulum